

# Hemi-exposure, as an alternative technique for conventional hemithyroidectomy

*Mohamed Ragheb, MD; Abdel Wahab Ezzat, MD; Ayman Abdel-Hafiz, MD;  
Ahmed Ibrahim, MD; Ahmed Hussein Tawfeek, MD*

*Department of General Surgery Ain-Shams University, Cairo, Egypt*

## Abstract

*The conventional (full thyroid exposure) technique of hemithyroidectomy normally requires a long collar incision, wide skin flaps on the anterior neck, a long midline opening of the strap muscles to provide exposure of one thyroid lobe, causing a wide neck scar and a variety of potential complications related to raising skin flaps and vertically opening the strap muscles. We developed a new surgical approach for a hemithyroidectomy, designed to minimize tissue trauma by obviating unnecessary tissue dissection, while maintaining adequate exposure, and named it hemi-exposure.*

*This study described this technique and the results compared with those achieved by full thyroid exposure technique.*

## Introduction:

With the widespread use of imaging studies including; ultrasonography (US), computed tomography (CT), and magnetic resonance imaging (MRI), as well as fine-needle aspiration biopsy, in the preoperative evaluation of nodular thyroid disorders, the extent of thyroidectomy required can be determined preoperatively in most of cases.<sup>1</sup>

Furthermore, the awareness of prognostic-factor analysis in the management of thyroid cancer patients has made it possible to determine whether a patient is in a low-risk or a high-risk group and to decide upon the most appropriate extent of thyroidectomy.<sup>2,3</sup>

Although there is some debate regarding the extent of surgery, a large number of low-risk cancer patients have been successfully treated with a conservative surgical approach.<sup>4,5</sup>

Throughout the previous 10 years, we extensively practiced and popularized the performance of hemithyroidectomy through a hemi-exposure technique in our department. The technique involves a direct muscle cutting approach to the thyroid lobe meant to be resected.

This study was conducted to evaluate this technique in terms of its merits as well as its safety and adequacy in the short as well as in

the long term follow up, in comparison to the traditional collar incision "full thyroid exposure" when hemithyroidectomy is preoperatively intended.

## Patients and methods:

Sixty patients were seen in Ain-Shams University Hospitals in the period from 2003 to 2006 managed by hemithyroidectomy for single lobe thyroid disease diagnosed preoperatively are included in this study. Thirty patients managed by a hemi-exposure technique (group A) and the other thirty patients managed by a full thyroid exposure technique (group B).

The adoption of either technique at this study was based on the surgeon preference.

Preoperative evaluation, operative details, post-operative complications and follow up were carefully noted.

All patients were subjected to full clinical assessment; including detailed medical history and thorough physical examination with special notes taken on onset of the neck lump, growth, hoarseness, pain, toxic manifestations, cervical lymph nodes and local tenderness. Routine laboratory studies and thyroid functions tests were done too.

All patients were subjected to ultrasound

examination of their neck to determine the nature of the nodule whether cystic, solid or mixed or a dominant nodule of a simple multinodular goitre. Fine needle aspiration cytology technique was done for five cases in group (A) and twelve cases in group (B).

Thyroid scintigraphy was done for patients presenting with clinically toxic symptoms and elevated thyroid hormonal profile.

CT scan of the neck was used in two cases of group (B), one with medullary carcinoma of the right thyroid lobe, the other had lobectomy many years ago and presenting with a hard nodule on the other side of the neck, voice changes and her neck U/S showing enlargement of the isthmus and the other lobe.

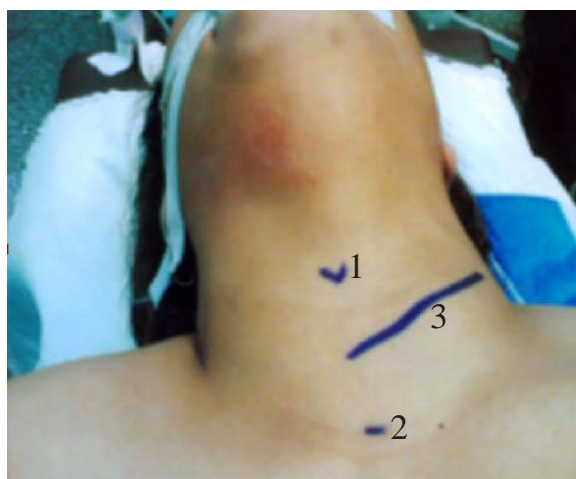### Surgical technique:

We did lobectomy through hemi-exposure technique for group (A) and lobectomy through conventional full thyroid exposure technique for group (B).

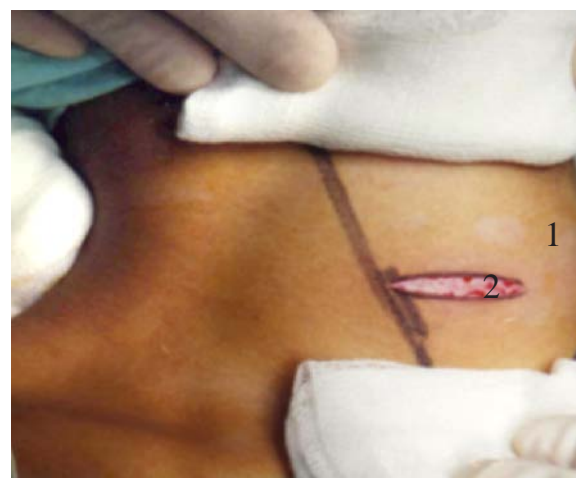### Hemi-exposure technique:

After the induction of general anesthesia, the patient is placed in the supine position with the neck extended. A 4-5 cm transverse incision is made on the side of interest along the lower skin crease **Figure(1a,b)**. The length of the skin incision depends on the lobe size. Upper skin-platysma complex is reflected as high as possible while the lower is left alone. The veins crossing the field are controlled by under running vicryl 3/0 at two sites to cut the pretracheal muscles inbetween. The anterior edge of the sternocleidomastoid muscle is dissected and retracted laterally. Then the strap muscles are cut transversely up on the same side exposing the anterior surface of the thyroid lobe **Figure(2)**. When the exposure is still inadequate, the incision is extended as necessary. With medial rotation of the gland by the assistant, the middle thyroid vein is ligated and divided if present.

Next, the thyroid lobe is retracted inferiorly and medially to expose the branches of the superior thyroid artery and vein; individually ligated and divided as close as possible to the upper pole **Figure(3)** and the superior laryngeal nerve was seen in 30% of cases in (group A) and 40% in (group B). The lobe and its lower pole.

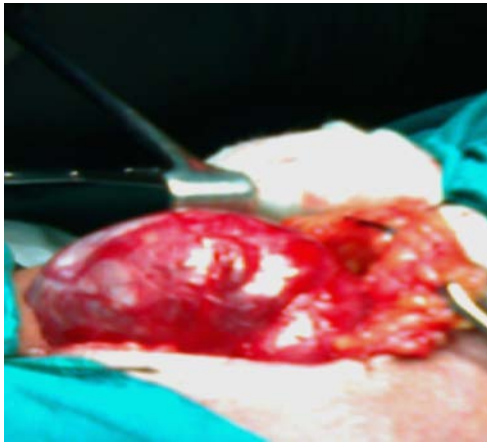

*Figure (1a): Five cm unilateral incision was labeled along the skin crease in the lower neck in 35 years old female with Lt solitary thyroid nodule (1 = thyroid cartilage; 2 = Suprasternal notch; 3 = hemi-exposure incision).*

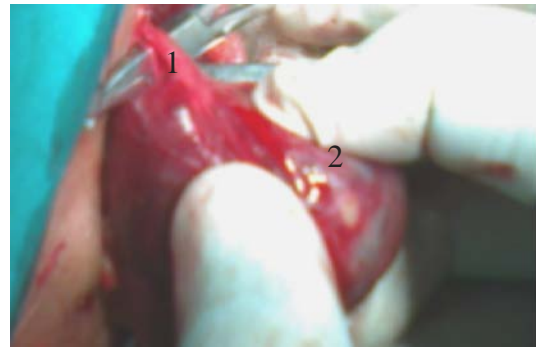


*Figure (1b): 3cm Left lower neck incision in female patient 20 years old with right solitary thyroid nodule (1 = The midline; 2 = hemi-exposure incision).*

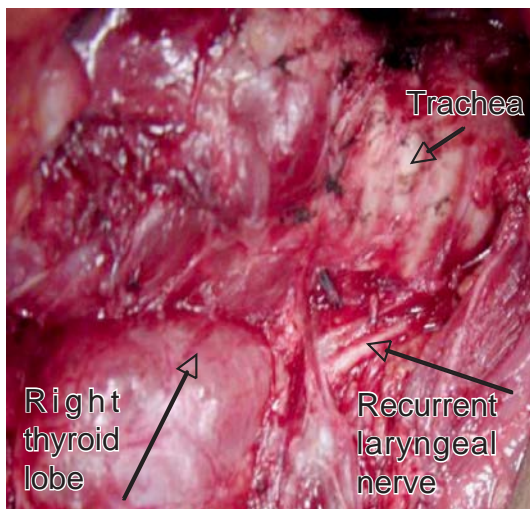
are then dissected, permitting elevation and medial rotation of the lower pole. After full mobilization of the superior and inferior poles, the dissected lobe is delivered from the wound as a specimen. A wide surgical field of the tracheo-thyroid space can be achieved by this technique and by lateral retraction of the wound end. Identification and preservation of the recurrent laryngeal nerve **Figure(4)**, and the parathyroid glands are identical to those used in the conventional full thyroid exposure technique for lobectomy. Ligation and division of inferior thyroid artery branches are carried out after the origin of parathyroid blood vessels. Finally the dense fascial attachment, being so-



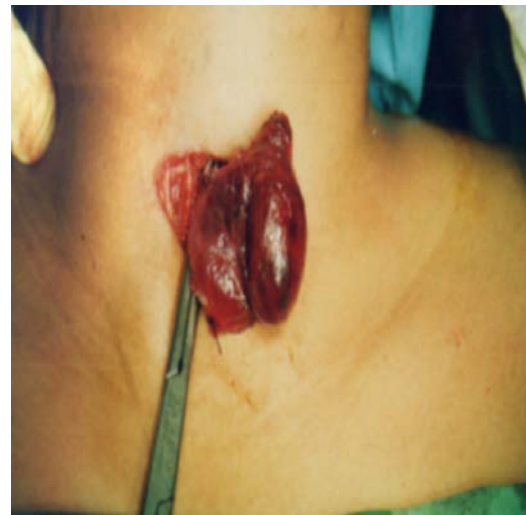*Figure (2): Easy delivery of the left thyroid lobe outside the hemi exposure (4cm) wound.*



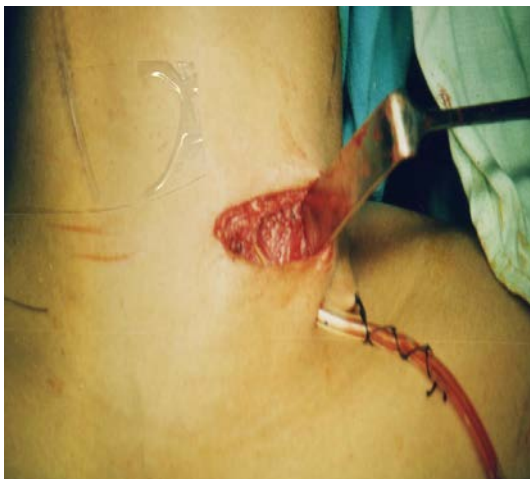*Figure (3): Individual dissection of the superior thyroid artery branches (1 = the anterior branch of superior thyroid artery; 2 = left thyroid lobe).*



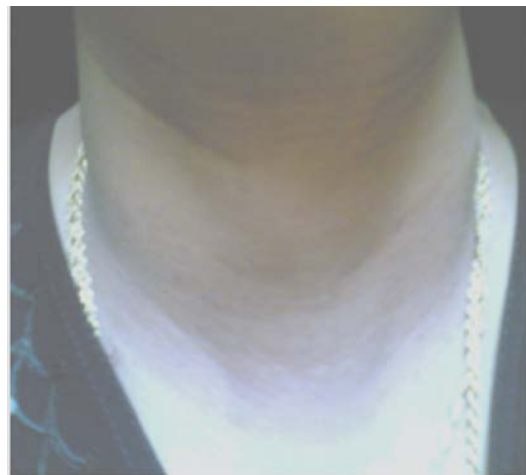
*Figure (4): Identification of the recurrent laryngeal nerve.*



*Figure (5): Left thyroid lobe and isthmus are completely delivered outside the wound.*



*Figure (6): Tube drain number 12 inside the left hemi-exposure wound.*



*Figure (7): 32 years old female, 2 years after hemi- exposure and completion thyroidectomy carried out for papillary carcinoma.*

called Berry's ligament, is carefully divided under direct vision using bipolar coagulation to control any minor bleeding. The isthmus is then dissected from the trachea by sharp dissection and cut flushed with the opposite side and cut edge of the remaining thyroid lobe is oversewn by a continuous or interrupted suture as the specimen is removed **Figure(5)**. The investing layer of cervical fascia over the strap muscles are reapproximated with interrupted 3/0 vicryl sutures with placing a number 12 tube drain of 10 cm length in the wound **Figure(6)**. The platysma and subcutaneous tissues are approximated in a similar fashion and the skin is closed using 3/0 vicryl subcuticular sutures.

#### Statistical methodology:

Analysis of data was done by IBM computer using SPSS (statistical program for social science) as follows: Description of quantitative variables as mean, standard deviation (SD) and range.

Description of qualitative variables as

number and percentage (%).

Chi-square test(x<sup>2</sup>): was used to compare qualitative variables.

Fisher exact test: was used instead of chi-square test when one expected cell or more are compared.

Unpaired t-test(t) : was used to compare two groups as regard quantitative variables.

P value >0.05 insignificant

P value <0.05 significant

P value <0.01 highly significant

#### Results:

There is no statistically significant difference between both studied groups as regard age, gender, different clinical parameters and different laboratory data.

**Table(1&2)** show that the average operative time in minutes was longer among full thyroid exposure group compared to hemi-exposure group with highly significant difference inbetween by unpaired t-test p<0.01. The average incision length in cm was longer among full thyroid exposure group compared

*Table (1): Comparison between both groups as regard patients, characteristics and complications of surgery.*

	Hemi-exposure N=30	Full -exposure N=30	T&X <sup>2</sup>	P
Median age	32±10	35±11	0.88	NS
Gender	4 M, 26F	6 M, 24F		NS
Operative time(min)	83	130	7.5	<0.001 HS
Length of incision(cm)	4.3	12.97	1.1	<0.001 HS
Hospital stay(days)	1.3	2.86	1.4	<0.001 HS
Operative complications:	3/30	8/30	0.86	NS
Recurrent laryngeal nerve injury	0	0		NS
Postoperative complications:				
Haematoma	0	2		
Blood loss(drain output)(cm <sup>3</sup> )	50	150		S
Transient hypocalcaemia	1	1		
Wound infection	0	2		
Hypothyroidism	1	1		
Keloid	1	2		

HS=Highly significant test

S= Significant

NS= Not significant

*Table (2): Comparison between both groups as regard completion thyroidectomy for malignancy.*

	<b>Hemi-exposure N=30</b>	<b>Full -exposure N=30</b>	<b>Statistical test</b>	<b>P</b>
No. of cases	3 cases (10%)	3 cases (10%)		
Operative time	1.15+0.8hr	2.5+0.9hr	t=2.5	<0.05 S
Complications:				
Transient RLN injury	0	(1 case)		
Transient hypocalcaemia	0	(1 case)		
Estimated blood loss(drain):				
First day post-operative	25 cc	100 cc		
Second day post-operative	15 cc	75 cc		

*RLN : Recurrent laryngeal nerve*

*S: Significant*

to hemi-exposure group with highly significant difference inbetween by unpaired t-test  $p<0.01$ .

The tables also show that full thyroid exposure group had more morbidity compared to hemi-exposure group as regard intra and postoperative complications and the longer period of hospital stay with highly significant difference inbetween by unpaired t-test  $p<0.01$ .

### **Discussion:**

The approach for management of thyroid nodules is to excise the mass completely and widely, which means almost always performing a lobectomy on the side of the lesion . If thyroid cancer was diagnosed later on permanent section analysis, for the remaining thyroid tissue, completion thyroidectomy will be carried out, followed by radioiodine treatment.<sup>6</sup>

Hemi-exposure technique for hemi-thyroidectomy, described in our study is technically nearly similar to full thyroid exposure technique, and each step in the procedure can be performed under the traditional view that most surgeons are familiar with.

The procedure differs from full thyroid exposure technique only in that it requires a smaller skin incision on one side, it involves a high transverse division of the strap muscles, and no much raising of skin flaps is necessary.

Hemi- exposure technique can obviate damage to the subcutaneous tissue and surgical trauma to the midline of the neck .

Even though the wound opening is small in hemi-exposure technique, sufficient exposure and dissection of the pretracheal and paratracheal spaces are present. This can be obtained by lateral retraction of the wound and anteromedial rotation of the specimen outside the open wound. So the access to the entire length of the recurrent laryngeal nerve, the parathyroid glands, and the lymph nodes along the tracheo-esophageal groove, can be done easily.

Minimally invasive technique is associated with shorter operation time, less blood loss and a shorter hospital stay, without compromising the extent of surgery. In addition, the cosmetic results are superior to those following conventional technique, especially on taking profile photography or cinema films for actors and actress **Figure(7)**.<sup>7</sup>

In hemi-exposure technique, completion thyroidectomy for any reason (malignancy, or recurrent goiter on the other side) is more feasible operation, as we will operate upon a virgin field, without adhesions from the previous hemi-exposure technique. On the other hand, full thyroid exposure technique will make the second operation difficult and the liability to injure the recurrent laryngeal

nerve and the parathyroid glands are higher as well as the time of the operation will be longer.

**Conclusion:**

The technique of hemi-exposure provides surgeons an adequate operative field and has proven to be simple, safe, fast and practical procedure for patients with single lobe thyroid disease.

For patients with huge goiters or retrosternal extension or locally advanced disease, full thyroid exposure technique may be preferable.

**References:**

- 1- Silverberg J, Gharib H: Endocrine tumors. In: Evaluation and diagnosis of nodular thyroid disease. Oxford: Blackwell; 1st edn. 1993; p. 233-242.
- 2- Tsuchiya A, Suzuki S, Kanno M, Kikuchi Y, Ando Y, Abe R: Prognostic factors associated with differentiated thyroid cancer. *Surg Today* 1995; (25): 778-782.
- 3- Hay ID, Grant CS, Bergstralh MS, et al: Unilateral lobectomy: Is it sufficient surgical treatment for patients with AMES low-risk papillary thyroid carcinoma? *Surg Today* 2002; 924:958.
- 4- Shaha AR, Shah JP, Loree TR: Low-risk differentiated thyroid cancer: the need for selective treatment. *Ann Surg Oncol* 1997; (4):328-333.
- 5- Park CS, Chung WY, Chang HS: Minimally invasive open thyroidectomy, *Surg Today* 2001; 31: 665-669.
- 6- Krukowski ZH: The Thyroid Gland and the Thyroglossal Tract. In: Bailey and Love's short practice of surgery. Charles VM, Russell RCG, William NS (editors); London: Arnold (Publishers); 24th edn. 2004; p. 776.
- 7- Ferzli S, Paul S, Ziad A, Robert N, Cacchione: Minimally invasive nonendoscopic thyroid surgery. *Ann Surg* 2001; 391-395.