

Laparoscopic Trans-hernial Sac Exploration for Diagnosis of Non-evident Hernia in the Contralateral Side. Is it Effective?

Alaa A. Elsayed, MD; Mohamed M. Khedre, MD

Department of Pediatric Surgery, Faculty of Medicine, Minia University, Egypt

Background: Congenital inguinal hernia is a very important subject for both general and pediatric surgeons, and many issues related to the inguinal hernia in infants and children are still confusing. Especially to explore the contralateral side or not.

Aim of the work: To assess the use of surgical laparoscopy in the diagnosis of the hernia in the unilateral and non - clinically visible on the other side and through the hernial sac.

Patients and methods: This is a prospective study that was held in the pediatric Surgery unit, Minia University Hospital on 100 patients who had unilateral congenital inguinal hernia between February 2016 and February 2018. Informed consents from parents of all patients were taken before entering the study.

Results: One hundred pediatric patients with unilateral inguinal hernia. Their age was up to 1 year, 28 patients were preterm and 72 patients were full term. Clinically, 54 of the patients had right-sided inguinal hernia, 46 had left-sided inguinal hernia. There were 58 males and 42 females. 38 of the clinical unilateral inguinal hernias were found to have a contralateral patent processus vaginalis or contralateral inguinal hernia, and all of these were repaired during the same operation. 5 patients developed complications (four cases of oedema and one case of haematoma). There were no wound infection and no recurrence.

Conclusion: This technique is useful for detecting contralateral hernia for infants having unilateral congenital inguinal hernia with non-evident hernia on other side who are less than one year especially in preterm babies.

Keywords: Surgical, laparoscopy, hernia sac, hernia, contralateral side.

Conflict of Interest: The authors have declared no conflict of interest.

Financial: None

Compliance with Ethics Requirements

All procedures followed were in accordance with the ethical standards of the responsible committee on human experimentation (institutional and national) and with the Helsinki Declaration of 1975, as revised in 2008.⁵ Informed consent was obtained from all patients included in the study.

Introduction

Inguinal hernia in infants and children is a surgical problem. The rational and timing of the repair, the need to explore the contralateral side, the value of laparoscopy, and anesthetic issues, remain unsettled. Inguinal hernias in both full-term and preterm infants are commonly operated once diagnosed to avoid incarceration of the hernia.¹

Inguinal hernia in children is directly related to the descent of the developing gonads. The testes are preceded in their descent to the scrotum by the processus vaginalis (PV), which is first seen around the 12th week of gestation, and it is usually obliterated between the 36th and 40th weeks of gestation. The distal part persists and becomes the

tunica vaginalis. In many newborns, this process is incomplete, leaving a patent processus vaginalis (PPV). Usually, the closure of PV is completed at birth; however, approximately 40% of patent processus vaginalis will close during the first months of life and an additional 20% close by 1 year of age. The processus vaginalis on the left side close before that on the right; therefore, 60% of congenital inguinal hernia occurs on the right side. The presence of PPV is necessary but not sufficient to develop a congenital inguinal hernia. About 12–14% of boys with PPV will develop inguinal hernia in their life time. The exact cause of the obliteration of the PPV is unknown. When PPV represents a sac through which abdominal contents can be herniated via the inguinal canal. However, sometimes the entrance

may be adequately covered by the internal oblique and transverses abdominal muscles, preventing escape of abdominal contents for many years, or allowing only fluid to pass through it forming a communicating hydrocele.^{2,3}

The inguinal canal is an oblique inter-muscular passage that begins by deep and ends by superficial inguinal rings and transmits the spermatic cord in males and round ligament in females. Most of the canal consists of the aponeurosis of the external oblique muscle as it curves inward to form the inguinal ligament. The roof of the canal is formed of the lower arched fibers of internal oblique and transverses abdominis muscles. The posterior wall of the canal consists of the transversalis fascia along its whole length. The inferior border of the canal is formed by the rolled fibers of inguinal ligament medially, and then the pectineus fascia and the insertion of the lacunar ligament (**Figure 1**). In neonates and infants, the inguinal canal is very short with both external and internal inguinal rings overlapping. Therefore, during herniotomy before 1 year of age, there is no need to open the external oblique muscle.^{4,5}

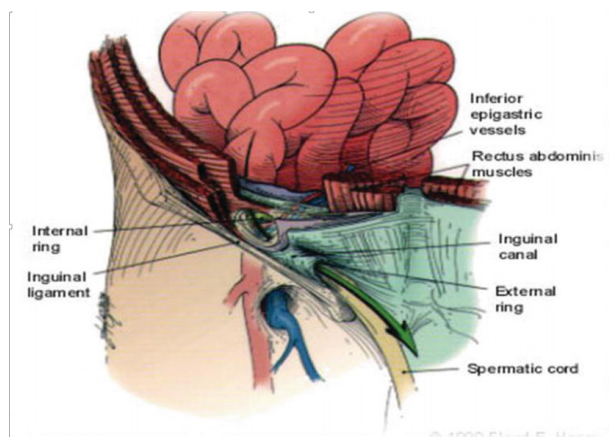


Fig 1: The open anatomy inguinal canal.

Laparoscopic anatomy

During laparoscopic hernia repair, the hernia is no longer viewed as an extrusion of a viscous from the peritoneal cavity. So, the layers of the inguinal region and the abdominal wall are viewed in a reversed order. Therefore, during laparoscopic hernia repair, the inguinal anatomy is visualized from inside with an optimal panoramic view of the posterior surface of the abdominal wall. Moreover, the inguinal anatomy is visualized with a paralyzed and expanded abdominal wall muscles. The pneumoperitoneum may change normal anatomy, tenses parietal peritoneum, stretches ligaments, and inflates hernial sac. This laparoscopic change modifies the tension, texture, and handling characteristics of the peritoneum and the abdominal wall muscles when compared with its normal characteristics found during laparotomy (**Figure 2**).^{6,7}

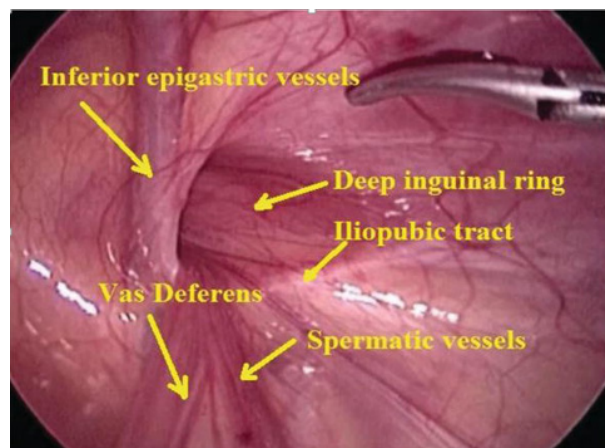


Fig 2: The laparoscopic view of inguinal anatomy.

Patients and methods

This is a prospective study that was held in the pediatric Surgery unit, Minia University Hospital on 100 patients who had unilateral congenital hernia from February 2016 to February 2018. Informed consents from parents of all patients were taken before entering the study.

a) Inclusion criteria

This study included patients with:

- Unilateral inguinal hernia less than 1 year of age.
- Both sexes

b) Exclusion criteria

This study excluded patients with: Bilateral inguinal hernia, recurrent hernia, complicated hernia. Patients who could not tolerate pneumoperitoneum (e.g., congenital heart disease and premature babies) or more than 1 year of age.

Methods

All the patients were subjected to the following work-up assessment and pre-operative procedures:

1. Through clinical assessment:

I. History taking.

II. Personal history: Name, Age, Sex and Address. History of present illness: Pain: swelling, disturbance of function, vomiting, constipation or distention.

III. History of other systems: as Urinary symptoms.

- History of investigations or medication.
- Past history: Common diseases and Previous operations.
- Family history: Consanguinity and Similar condition in one of the members of the family.

2. Examination

A - General examination

- Vital signs: Temperature, Heart rate, Respiratory rate and Blood pressure using an appropriate sized cuff.

- General look: Conscious, Alert, Toxic, Body built and Decubitus.
 - Head, Neck, Chest and Heart examination.
- B - Local examination**
- Inguinal and groin regions.
 - Scrotum and its contents.
 - Site and size.
 - Reducibility or any underlying straining for micturition.
 - Presence or absence of the testis in the scrotal sac.

3. Laboratory Work-Up: Routine laboratory tests including: Complete blood count (CBC), coagulation profile (Prothrombin time concentration, INR, urea and creatinine).

4. Preoperative fitness: Consulting the pediatric & anesthesia physicians:

- Surgical techniques: The procedure was performed under controlled general anesthesia with endotracheal intubation.
- Patients were kept supine with head low along with elevation of the side of the hernia to be repaired, i.e. if operating for right inguinal hernia left lateral tilt to the operating table was given, with sterilization of abdomen and groin sterilely prepped. The stomach was emptied with a suction catheter and the bladder using urinary catheter, where older children are asked to urinate prior to entering the operating room. Classic open herniotomy was done through a transverse incision in the lowest inguinal skin crease above the external inguinal ring on the affected side after incision of Scarpa's fascia

was incised and the superficial inguinal ring was identified, the external oblique fascia was opened superiorly in the long axis of its fibers, perpendicular to the ring. Delivery of the spermatic cord, cremasteric muscle opened by blunt dissection. The sac was elevated anteromedially and the spermatic vessels are identified and carefully dissected free from the diverticular structure of the inguinal hernia sac.

- Once the spermatic vessels and vas deferens were mobilized away from the sac, the hernial sac was divided between clamps and the upper end dissected superiorly to the level of the internal (deep) inguinal ring.
- The proper extent of the superior dissection was identified by the presence of retroperitoneal fat at the neck of the sac. At this point, the sac was opened on the most distal end and a 5mm trocar was advanced into the abdomen and secured with a tie to minimize insufflation leak.
- The abdomen was insufflated with CO2 to 5–8 mmHg pressure and a 45° laparoscope was advanced through the trocar into the abdomen to view the opposite internal ring.
- It was of advantage to have the patient in some degree of Trendelenburg position to aid the bowel in moving out of the pelvis and away from the contralateral internal ring. The positioning of the contralateral inguinal ring lied laterally to the lateral umbilical fold.
- The vas deferens in the male and the round ligament in female were traced over the pelvic brim to reach the internal inguinal ring. **(Figure 3).**

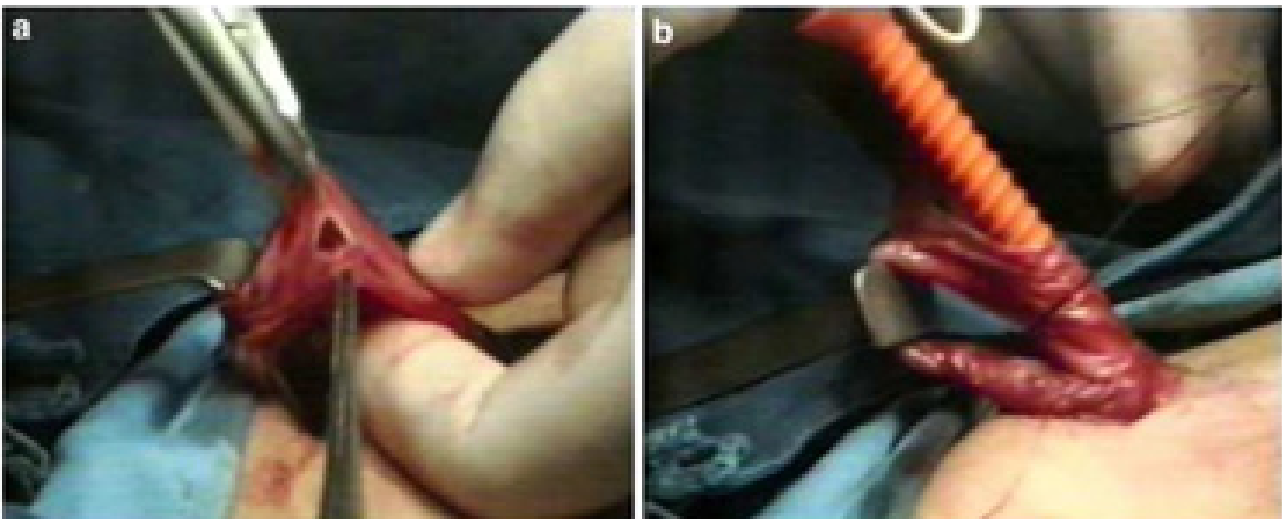


Fig 3: Transinguinal approach to the contralateral side in unilateral hernia repair.

- Following insertion of a re-usable trocar through the ipsilateral hernial sac, the port was secured in place with a suture.
- Viewing the left internal ring via the right

inguinal hernia sac **(Figure 4)** a normal internal ring with the vas deferens medially and the spermatic cord vessels laterally. There was no inguinal hernia evident.

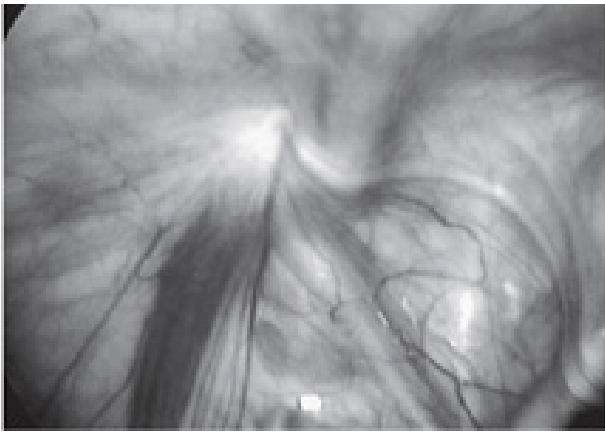

Fig 4: Intact left inguinal ring.

While viewing the right internal ring via the left inguinal hernia sac, a large indirect inguinal hernia was noted with weakening of the inguinal floor. (**Figure 5**).

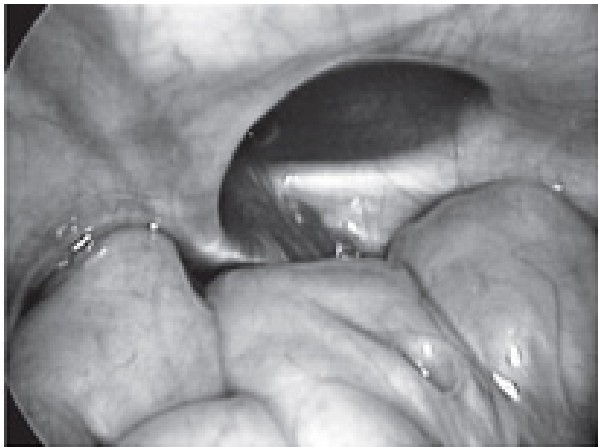


Fig 5: Large right internal ring defect.

- Following laparoscopy, the trocar was removed and any contents in the sac were reduced into the peritoneal cavity. The base of the sac was twisted to ensure that all the contents were fully reduced. If contents seemed to remain within the sac, one should suspect a sliding component within the posterior wall of the sac.
- Sliding hernias often present as a more chronic hernia with the bulge often noted for a prolonged period of time prior to referral. In these instances, a viscus is usually a component of the sac and occasional opening the sac, and delicately dissecting the intra-abdominal structures off the sac.
- Following reduction of the sliding component into the abdomen, a high ligation of the sac at the internal ring can then be safely carried out. The neck of the sac is transfixed twice

with absorbable 4/0 (or 3/0 in older children) suture ligature.

- Wound closure is accomplished with an interrupted or running absorbable 4/0 suture approximating the external oblique fascia leaflets to the external ring. Scarpa's fascia is closed with one or two interrupted 4/0 absorbable sutures. The skin edges are opposed with either interrupted or running subcuticular 4/0 or 5/0 absorbable sutures. The skin edges are approximated with sterile skin closure strips (e.g. Steristrips) and a semipermeable adhesive film dressing is applied in older children.
- Caudal block may additionally be used regarding parental consent. Otherwise, it was preferable to infiltrate sites prior to skin closure using local anesthetics. (All incisions are infiltrated with bipivacaine 0.25 percent, use 0.25 mL/ kg per hernia repair side for a maximum of 3 mg/kg dose) reduce postoperative pain.
- In patients with a contralateral PPV, a simultaneous repair is accomplished. The presence of a significant peritoneal opening, the absence of an identifiable termination of the peritoneal sac, visualization of bubbles internally with external pressure, a hidden opening under a veil of peritoneum, a probing depth of 1.5 cm or concentric peritoneal rings distal to the internal ring are regarded as positive findings of patency.
- A negative exploration means a flat or tenting peritoneal fold appearing as a shallow disk with a visible base at the internal inguinal ring.
- Herniotomy and high ligation were performed after decompressing the abdomen and terminating laparoscopy. Postoperative care: Most patients were discharged from the surgery room within 2 hours of operative repair. Oral intake was resumed when the child awakened. Analgesic was used for approximately 48 hours following the procedure. Baths were resumed on postoperative day 3. There are no activity restrictions for infants, but older children should refrain from bicycle riding or other vigorous physical activity until their pain has subsided. Treatment of routine inguinal hernias usually includes a postoperative clinic visit and follow up after 1 week post-operative then every 2 weeks till 6 months.
- Follow up included: oedema, hematoma, wound dehiscence and recurrence.
- Statistical analysis
- Statistical analysis was done using PSPP, test χ^2 and p-value.

Results

- One hundred pediatric patients with unilateral inguinal hernia were operated by classic technique followed by laparoscopic Trans-hernial sac exploration of the other side. Their age is up to 1 year.
- 28 patients were preterm and 72 patients were full term. Clinically, 54 of the patients had right sided inguinal hernia and 46 had left sided inguinal hernia. The cases were 58 males and 42 females. **(Table 1).**

Table 1: Demography of 100 patients

Different parameters		
Sex	58 male	42 Female
Age	28 preterm	72 fullterm
Site of I.H	54 ROIH	46 LOIH

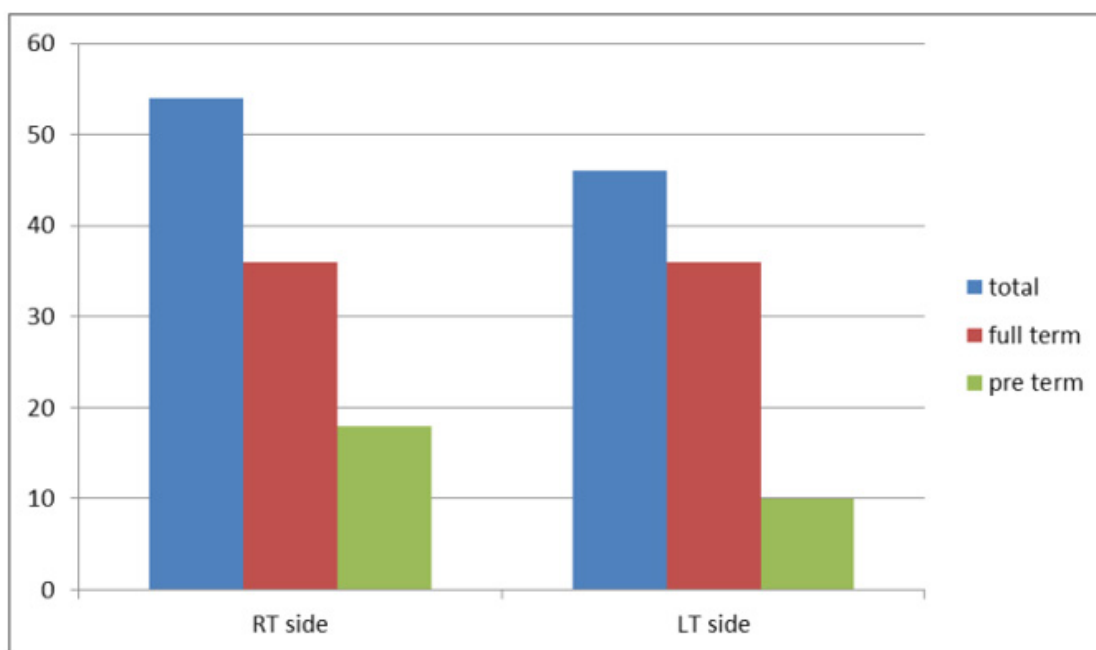


Fig 6: Relations between side of hernia and time of delivery.

- Intra-operatively, 38 of the clinical unilateral inguinal hernias were found to have a contralateral patent processus vaginalis or contralateral

inguinal hernia, 22 on left side and 16 on right side. All of these were repaired during the same operation.

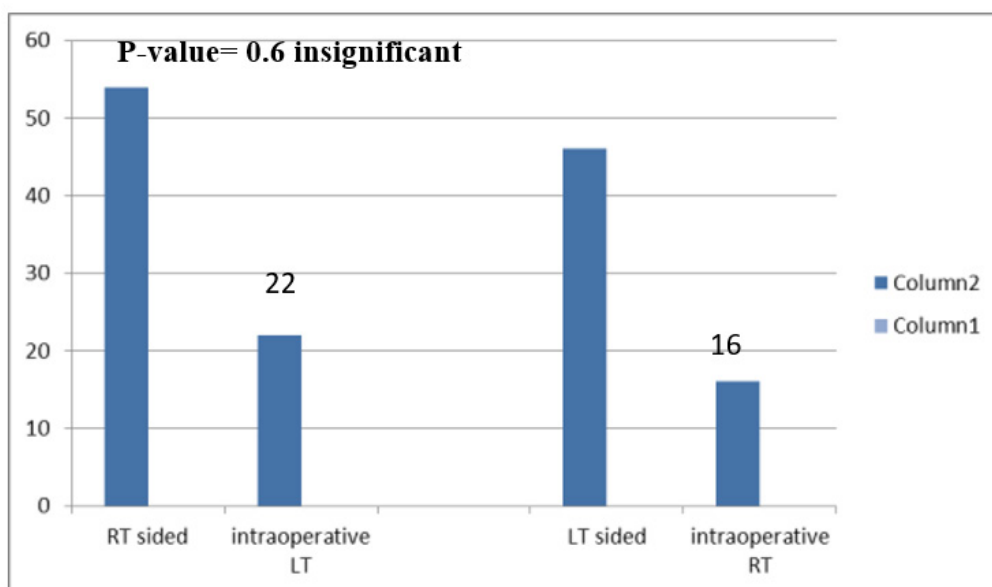


Fig 7: Intra operative positive finding of contralateral side.

Postoperatively, 72 patients were discharged the same day of the operation. 28 patients were discharged on the second postoperative day. All of these patients were pre term, 6 patients for delayed recovery, 2 patients for postoperative apnea, and 7 patients were residing far away from the hospital. (Table 2).

Table 2: Post-operative discharge (hospital stay)

Site of hernia	The same day	Next day	Total
Rt sided	38 (70.4%)	16(29.6%)	54 (100%)
Lt sided	34 (73.9%)	12 (26.1%)	46 (100%)

Table 3: Postoperative follow up

Post-operative follow up		NO	%
Non complicated cases		89	89%
Complicated cases	Severe edema	10	10%
	Haematoma	1	1%
	Wound dehiscence	No	0%
	Recurrence	No	0%
		Total 11 cases	Total 11%

Discussion

Inguinal hernia is a very common condition in children and adults and is the most common operation performed on children (other than ritual circumcision). Since the classic open surgery in pediatric patient was introduced (the standard repair involves a small groin incision on the affected side, with or without incision of the external oblique muscle and opening of the external ring, dissection of the hernia sac, and high ligation and excision of the sac), it has become the standard operation for hernias, with very few controversies: whether the surgeon should perform only a herniotomy, whether a contralateral groin exploration be performed. The operation is quick, safe, and can be done in an outpatient setting with anesthesia via a laryngeal mask. The recurrence rate is acceptable, 1-3%, depending on the expertise of the surgeon, the child age and concomitant diseases. Until laparoscopy developed, there was controversy regarding whether a contralateral groin exploration should be performed and to whom. On the one hand, an exploration ensured a diagnosis during one operation and anesthesia, an option that carries many advantages to the patient and the parents. On the other hand, most of these explorations performed on children above the age of 1 year were negative and doubling the operating and anesthetic time. Therefore, most surgeons had loosely based criteria on which the exploration was performed. Since a hernia can be very easily and accurately

Postoperative follow up revealed that 10 patients developed complications severe of oedema and one case haematoma). There were no wound infection and no recurrence (Table 3).

diagnosed from within the peritoneum, introduction of a laparoscope during the operation seemed like a natural answer for the question.

This study was done on one hundred patients suffering of unilateral inguinal hernia, just to study the Role of trans-hernial sac laparoscopic detection of clinically non evident contralateral congenital hernia in pediatrics.

This study was done in pediatric surgery unit at Minia Hospital University. The study started from February, 2016 to February 2018. Most of the patients were treated between the age group of up to 3 months, 28 patients were preterm.

Incidence is highest in patients less than six month especially at premature infants. The incidence may be as high as 60% in infants born at 500-750 g. Nearly one-third of infants with a birth weight less than 1000 g will develop an IH. Term infants have an IH incidence of 3-5%. The overall incidence of childhood inguinal hernia is 0.8-4.4%.⁸ 58 males and 42 females were candidates for the research with a ratio nearly 1.4:1 respectively, close to the normal ratio varies 2:1.

In our study 28 patients were preterm and 72 were full term, that 38 patients had positive other side (38%). On Right side (22/58) 37.9% and on Left side (16/42) 38%. 16 patients from preterm

infants had contralateral hernia (16/28) 57%. The incidence of a contralateral, asymptomatic groin hernia [16/45 (35.5%) on the right sided hernia, and 4/10 (40%) on the left sided hernia],⁹ The incidence of a contralateral, asymptomatic groin hernia in children [20/55 (36.4%)]. vary from 10% to 60%, depending on prematurity of the child.

In our study, the mean operative time for unilateral hernia repair was 35 minutes (± 9 minutes). The mean difference in time between unilateral and bilateral hernial repairs was about 10 minutes. In 2010, the study of Aaron and his colleagues the operative time for unilateral hernia repair was 28-43 minutes and for bilateral 38-50 minutes. Operative time for unilateral hernia repair was 25-40 minutes and for bilateral 34-48 minutes.⁸

In our study, postoperatively 72 patients were discharged at the day of the operation but 28 patients were discharged on the second day all of them were preterm cases that 6 patients for delayed recovery 2 patients for postoperative apnea and the others were residing away from the hospital. (72/100) 72%.

At other studies postoperative discharge had range about 77% discharged at the same day.

In our series, we had only minor complications that occurred in 11 cases only. 10 patients had severe scrotal edema and one case had hematoma with no wound infection or recurrence which is comparable to the complication, and recurrence rate reported in similar series, and most large series of open inguinal hernia repairs.

Ibrahim⁹ reported no complications in 28 patients, and 1 recurrence, there were no complications or recurrences in this series, In 2010, Aaron and his colleagues They had no Intraoperative complications, with recurrence rate of (0.83%).

Conclusion

One can recommend routine use of this technique

for infants having unilateral congenital inguinal hernia with non-evident hernia on other side, whom less than one year especially preterm babies.

References

1. Helal AA: Inguinal Hernia in Infancy and Children. InHernia. IntechOpen. 2017.
2. Bharathi RS, Arora M, Baskaran V: How we "SEAL" internal ring in pediatric inguinal hernias. *Surgical Laparoscopy Endoscopy & Percutaneous Techniques*. 2008; 18: 192-194.
3. Bharathi RS, Arora M, Baskaran V: Minimal access surgery of pediatric inguinal hernias. *A review. Surgical Endoscopy*. 2008; 22: 1751-1762.
4. Canes D, et al: Transumbilical single-port surgery: Evolution and current status. *European Urology*. 2008; 54: 1020-1029.
5. Chang YT, Wang JY, Lee JY: A simple single-port laparoscopic assisted technique for completely enclosing inguinal hernia in children. *The American Journal of Surgery*. 2009; 198: 13-16.
6. Chang YT: Technical refinements in single-port laparoscopic surgery of inguinal hernia in infants and children. *Diagnostic and Therapeutic Endoscopy*. 2010; 1-6.
7. Chen K, Xiang G, Wang H, Xiao F: Towards a near-zero recurrence rate in laparoscopic inguinal hernia repair for pediatric patients. *Journal of Laparoendoscopic & Advanced Surgical Techniques. Part A*. 2011; 16.
8. Khoo AK, Cleeve SJ: Congenital inguinal hernia, hydrocoele and undescended testis. *Surgery (Oxford)*. 2016; 34(5): 226-231.
9. Ibrahim, R: Laparoscopic Inguinal Hernia Inversion And Ligation In Pediatric Female Patients, The Egyptian experience. *AAMJ*. 2013; 11 (4).