

# End-loop Stoma versus the Traditional Two Separate Stomas after Intestinal Resection

*Wafi Fouad Salib, MD; Ramy Mikhael Nageeb, MD;  
Mohamed Abd El-Monem Abd El-Salam Rizk MD.*

*General Surgery Department, Vascular Surgery Department Ain Shams  
University, Cairo, Egypt.*

**Aim:** To compare the technique of temporary partial intestinal anastomosis versus two separate stomas, following large bowel resection, in patients where the anastomosis is anticipated to have borderline margins with dubious viability.

**Patients and methods:** Thirty patients underwent bowel resection, Group A (15 patients) had partially anastomosed end-loop stoma and Group B (15 patients) had traditional two stomas technique. These operations were performed at the Ain Shams University Hospitals between November 2011 and October 2013. Patients with marked difference in the diameter between the cut ends of bowel loops after resection were added to the study. Bowel resection was performed because of conditions such as ischemic colitis, bowel mass and bowel injury.

**Results:** Significant decrease in the intraoperative time was found where end loop stoma was constructed and also the operative time of stoma closure to regain bowel continuity in group A. As regard the complications, postoperatively, 1 of the patients of group A developed parastomal hernia and one patient of group B developed stoma necrosis which necessitated refashioning of the stoma. There were no major complications in group A. All patients were discharged between the 8th and 15th day after the procedure, and the stoma was closed 3 weeks to 12 weeks later.

**Conclusion:** We believe that end-loop stoma is a simple, quick and safe technique with minimal stoma-related morbidity, and with simple and safe reversion. This technique can be considered as a useful option in the treatment of ischemic enteritis, and in the management of severe intestinal trauma.

**Key words:** Endloop stoma, separate stoma, resection.

---

## Introduction:

The rodless end-loop stoma described by Prasad et al.<sup>1</sup> is a simple modification of a loop stoma with several important advantages. First, it is technically easy to construct.<sup>2,3</sup> Second, it does not require a supporting rod or a separate opening in the abdominal wall for a mucous fistula.<sup>4-7</sup>

These advantages facilitate stoma care because a single circular ostomy device readily covers the openings of both the proximal and distal limbs without the interference of a rod.<sup>2</sup> End-loop stomas are also easy to close. Laparotomy is not required for subsequent removal. Because the proximal and distal segments are located on a site of stoma,

peristomal approach can almost always be used to restore intestinal continuity.<sup>8</sup> This fact is a distinct advantage of the end-loop stoma over the more traditional approach of dealing with the divided ends of the colon in cases where immediate colo-colic anastomosis is inadvisable after left hemicolectomy (e.g., proximal colostomy and distal mucous fistula after penetrating trauma to the left colon).<sup>9,10</sup>

Our aim of this study is to compare the technique of temporary posterior wall intestinal anastomosis versus two separate stomas, following bowel resection, in patients where the anastomosis is anticipated to have borderline margins with dubious viability.

## Patients and methods:

Thirty patients underwent enterectomy, of them, fifteen patients (group A) had partially anastomosed end-loop ileostomy while the other fifteen patients (group B) had traditional two stomas technique at the Ain Shams University Hospitals between November 2011 and October 2013. The patient's mean age at stoma formation was 46 years (range 22-70 years). There were 11 females and 19 males. All patients were subjected to a midline exploratory laparotomy. Enterectomy was performed secondary to mesenteric vascular occlusive disease, bowel mass and small bowel injury.

Classical resection of bowel masses (either for benign cause e.g. Inflammatory mass or for malignant tumors) down to the main supplying vessels was done in 13 patients, 5 of them were found in the splenic flexure and 8 patients had sigmoid mass. In these cases, the usual presentation was intestinal obstruction, so, the marked variation of the diameter of both intestinal ends; a doubtful vascularity, the presence of inflammatory reaction (pus) and the lack of preoperative bowel preparation were indications to bring these ends out as a stoma.

Ischemic colitis disease was found in 3 patients, 2 patients had inferior mesenteric artery thrombosis while one patient had inferior mesenteric arterial injury after open abdominal aortic surgery. Resection of the gangrenous part in these cases was done followed by exteriorization due to questionable viability of the edges. 13 patients had bowel trauma (6 patients to the transverse colon, 5 patients to the left colon and 2 patients to the sigmoid colon). Limited resection of the affected bowel followed by stoma formation was performed in these cases either due to very bad general condition, associated vascular injury or leakage from previous anastomosis. One case presenting with large intestinal obstruction due to colo-colic intussusception which proved later to be due to large benign colonic polyp. The Demographic data and the clinical characteristics of patients are shown in **Table (1)**.

## Surgical technique:

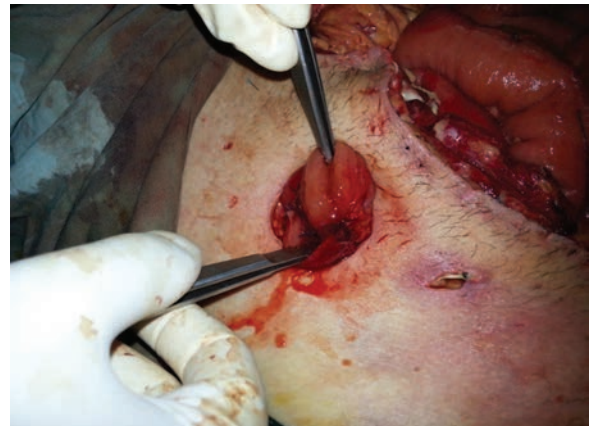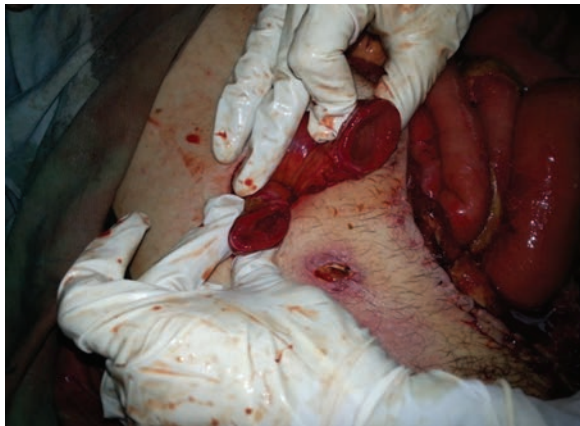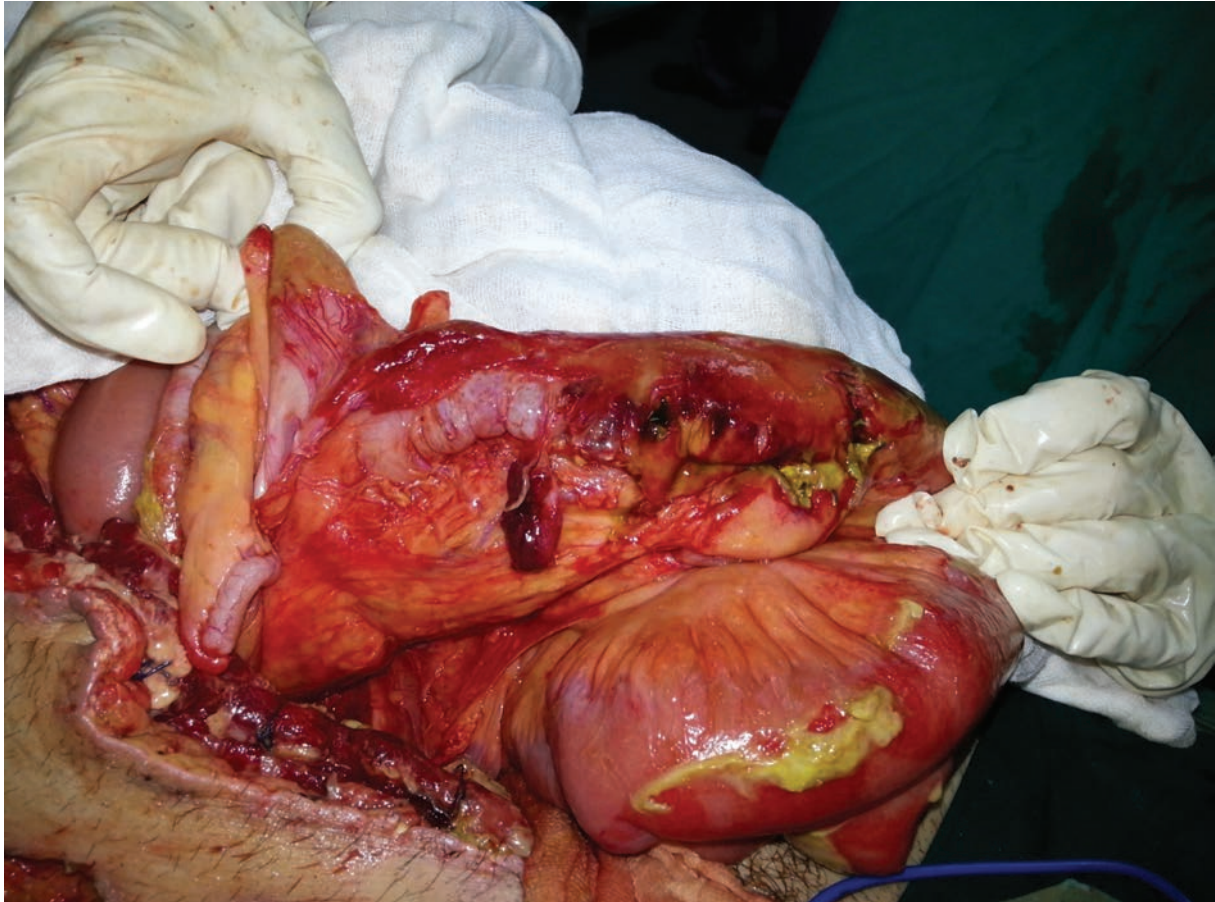
Preoperatively every patient had a single dose of 3rd generation cephalosporin and the bladder was catheterized after onset of anesthesia.

After abdominal exploration through a midline incision, a circle of skin was excised and an opening was made at the edge of the rectus muscle as for an end stoma. The intestine was divided manually or with a linear-cutting stapler at a point where both the proximal and the distal limbs of the intestine could be brought through the opening in the abdominal wall without tension or torsion.

Then, in group A, the staple line of both intestinal loops was excised (if a linear-cutting stapler was used) and a single, full-thickness suture between the posterior walls only was undergone. This was a modification of the original technique which the staple line of proximal limb was excised completely and only the antimesenteric corner of the distal staple line was removed. Then, the proximal limb was matured flush with the skin by suturing full-thickness skin to sero-muscular intestinal wall with absorbable sutures. In group B, two classical stomas were done with a bridge of skin in-between and the abdomen was closed in layers as usual.

Postoperatively, the patients started oral intake as soon as signs of intestinal movement was achieved with regular follow up in the outpatient clinic for stoma care and any complication related to it.

Closure of the stoma was performed 3 to 12 weeks later according to the patient general condition and associated diseases or other organ injuries. In group A, the stoma was brought down via circular incision around, followed by dissection down to the abdominal cavity, then two layered anastomosis between the intestinal ends was performed and the wound was closed in layers. In group B, closure of the stomas in 9 cases required re-opening of the abdomen to restore intestinal continuity via midline incision and dissection of both stomas then classical two layered anastomosis was done and the abdomen and the sites of the previous stomas were closed in layers as usual and in



*Figure (1): This is a case of leakage after intestinal resection due to penetrating abdominal trauma. The lower two photos are showing end-loop stoma before and after anastomosing the posterior walls of intestinal loops cut ends.*

the other 6 cases dissection of both stomas with the removal of skin bridge in between was the technique to restore the intestinal continuity.

**Results:**

Thirty patients were included in this study, 19 males (63%) and 11 females (27%), mean age at stoma formation was 46 years (range

22-70 years), of which 13 patients (43.3%) had bowel resection due to bowel mass, 13 patients (43.3%) due to bowel trauma, 3 patients (10%) due to ischemic colitis and one patient (3.3%) due to colo-colic intussusception.

There was a significant difference between both techniques concerning the intra-operative time. The traditional two stoma

**Table 1: The Demographic data & the Clinical characteristics of the study patients.**

	<b>Group A</b>	<b>Group B</b>	<b>Total</b>
Number of patients	15	15	30
Male	11	8	19
Females	6	5	11
Age(average)	46.5	43.5	46
Causes of enterectomy:			
Bowel mass:	6	7	13
Ischemic colitis:	2	1	3
Bowel trauma:	7	6	13
Others:		1 (colo-colic intussusception)	1

technique had longer intra-operative time (average 36 minutes) than the end-loop stoma (average 15 minutes).

There are no particular complications for the end-loop stoma. There were no major complications apart from one case (6.6%) in group A developed parastomal hernia which was managed conservatively and repair was done in the same session during closure of the stoma. One patient (6.6%) of group B developed stoma necrosis which necessitated refashioning of the stoma. Two patients (13.3%) of group B developed mild wound infection which was managed conservatively with local measures. All patients were discharged between the 8<sup>th</sup> and 15<sup>th</sup> day after the procedure.

During regular follow up of those patients, and with inquiring about any problems related to stoma care, 12 patients (80%) of group A reported that stoma care was easy and convenient to care while only 5 patients (17%) of group B were satisfied with their stoma.

The stoma was closed 3 weeks to 12 weeks later and therefore appeared another significant difference between both techniques and that was all patients who had end loop stoma were re-anastomosed without the need to reopen the abdomen while in group B 9 patients (60%) required their abdomen to be reopened due to the distant two separate stomas and the other 6 patients (40%) needed to remove a skin bridge. Therefore, the intra-operative time in the 2<sup>nd</sup> operation was much

increased in group B (average 125 min.) in comparison with group A (average 60 min.).

#### **Discussion:**

The first surgical stoma was created 200 years ago. The earliest stomas were actually unintentional ones, enterocutaneous fistulas resulting from penetrating abdominal injuries or complications of intestinal diseases such as incarcerated hernias. Bowel enterostomies were occasionally required following emergent bowel resection in conditions such as bowel ischemic, and inflammatory or traumatic disorders. The clinical setting of these patients requires a quick and safe procedure. Furthermore, the restoration of intestinal continuity usually requires meticulous dissection of the afferent and efferent segments and the formation of a new anastomosis, usually under general anesthesia.<sup>13</sup>

Even a loop or “end loop” stoma requires an anastomosis for its closure, as well as peritoneal breaching for the intra-abdominal position of the anastomotic segment.<sup>11</sup>

Because of the aforementioned reasons, closure itself is associated with complications such as bowel obstruction (0%-15%), anastomotic leak (0%-8%), fistula formation (0%-7%), wound infection (up to 18%) and development of hernia at the stoma site (1%-12%).<sup>6</sup>

In the present study, the anastomotic stoma was discussed, a “partially anastomosed end-loop ileostomy” for the treatment of adult

patients, who presented with conditions such as intestinal necrosis due to mesenteric vascular occlusive disease and intestinal trauma with macroscopically borderline margins with respect to the viability of the intestinal wall after extended bowel resection.

The procedure requires less time in comparison to a conventional two stoma technique. The formation of such a stoma was simple and quick, with no risk of stenosis or kinking. The short duration of this technique is an important advantage since operative time is a critical factor in the survival of these patients (urgent cases, unstable patients, “damage control” in trauma).

The patients who had end loop stoma reported higher level of satisfaction as regard stoma care (80%) in comparison to 17% of the other group of patients. This can be explained by the fact that caring of one stoma is much easier and controllable by the patients than two stomas apart. Also, the area of skin irritation or inflammation is much reduced in one stoma technique leading to less patient complaining of their stoma and more satisfaction.

One case of our study developed parastomal hernia in the group of end-loop stoma. This may be (theoretically) due to the fact that larger stoma size is recommended to bring both loops out from it but further larger scale studies are recommended to show its significance.

In addition, closure of the stoma can be performed easily and quickly without formal midline laparotomy, so, the intraoperative time in the second operation will be much reduced in closure of the end-loop stoma, moreover, avoiding the possible complication related to reopening the abdomen as iatrogenic intestinal injuries due to excessive adhesions, wound complications or incisional hernia. Some surgeons reported a technique to prevent reopening the abdomen in the group of patients with two stomas via removing the skin bridge in between the stomas and incision of the abdominal wall muscles. We think that this method is more difficult than end-loop stoma because it requires the two loops to be very close to each other, with difficult

application of stomadhesive and also needs more skin to be excised and theoretically this may predispose to incisional hernia.

### Conclusion:

We believe that end-loop stoma is a simple, fast and safe technique with minimal stoma-related morbidity, and with simple and safe reversion. It should be considered as a useful treatment option in patients with ischemic enteritis and in the management of severe intestinal trauma.

### Reference:

- 1- Prasad ML, Pearl RK, Orsay CP: End-loop ileocolostomy for massive trauma to the right side of the colon. *Arch Surg* 1984; 119: 975–976.
- 2- Kaidar-Person O, Person B, Wexner S: Complications of construction and closure of temporary loop ileostomy. *J Am Coll Surg* 2005; 201: 759–773.
- 3- Shellito PC: Complications of abdominal stoma surgery. *Dis Colon Rectum* 1998; 41: 1562–1572.
- 4- O'Toole GC, Hyland JM, Grant DC, Barry MK: Defunctioning loop ileostomy: A prospective audit. *J Am Coll Surg* 1999; 188: 6–9.
- 5- Garcia-Botello SA, Garcia-Armengol J, Garcia-Granero E, Espi A, Juan C, Lopez-Mozos F, Lledo S: A prospective audit of the complications of loop ileostomy construction and takedown. *Dig Surg* 2004; 21: 440–446.
- 6- Mosdell DM, Doberneck RC: Morbidity and mortality of ostomy closure. *Am J Surg* 1991; 162: 633–636; discussion 636-637.
- 7- Lange R, Dominguez Fernandez E, Friedrich J, Erhard J, Eigler FW: The anastomotic stoma: A useful procedure in emergency bowel surgery. *Langenbecks Arch Chir* 1996; 381: 333–336.
- 8- Hasegawa H, Radley S, Morton DG, Keighley MR: Stapled versus sutured closure of loop ileostomy: A randomized controlled trial. *Ann Surg* 2000; 231: 202–204.
- 9- Hull TL, Kobe I, Fazio VW: Comparison of handsewn with stapled loop ileostomy closures. *Dis Colon Rectum* 1996; 39: 1086–1089.
- 10- Bakx R, Busch OR, Bemelman WA, Veldink GJ, Slors JF, van Lanschot JJ: Morbidity of temporary loop ileostomies. *Dig Surg* 2004; 21: 277–281.

- 
- 11- Feinberg SM, McLeod RS, Cohen Z: Complications of loop ileostomy. *Am J Surg* 1987; 153: 102–107.
  - 12- Wong KS, Remzi FH, Gorgun E, Arrigain S, Church JM, Preen M, Fazio VW: Loop ileostomy closure after restorative proctocolectomy: Outcome in 1,504 patients. *Dis Colon Rectum* 2005; 48: 243–250.
  - 13- Aziz A, Sheikh I, Jawaid M, Alam SN, Saleem M: Indications and complications of loop ileostomy. *Journal of Surgery Pakistan (International)* 2009; 14 (3): 128–131.