

Neck ultrasound & sestamibi scan, either or both for better detection and localization of hyperfunctioning parathyroid gland(s)

*Ashraf Hegab, MD; Mohammed A Nada, MD; Waft Fouad Salib, MD;
Mohamed Seif, MD; Esam F Ebeid, MD; MRCS, (Eng);
Abdel Wahab Ezzat, MD*

Department of General Surgery, Ain Shams University, Cairo, Egypt.

Abstract

Aim of the work: To evaluate the usefulness of the combination of sestamibi scintigraphy (SS) and neck ultrasonography (US) in patients with primary hyperparathyroidism (pHPT) undergoing parathyroidectomy.

Patient and methods: Seventeen patients with proved pHPT were studied, excluding patients with persistent or recurrent disease. All patients underwent both SS and US prior to surgery, and the results were compared with operative and histological findings.

Results: Fourteen patients had single adenoma, 2 patients had hyperplasia and a single patient had multiple adenomas. US detected and localized accurately 10 cases, SS detected and localized the diseased parathyroid gland in 14 cases, while with combination we detected and localized the diseased parathyroid glands in 16 patients .

Conclusions: When the preoperative localization of the PT glands is chosen, the combination of SS and US represents a reliable noninvasive localization technique and should be considered for use in a complementary way beginning with US and if US couldn't localize the diseased gland SS will be the next step.

Introduction:

Primary hyperparathyroidism (pHPT) is a common condition. The incidence since the introduction of multichannel analyzers is approximately 1:1000.1 In women over 60 years of age the average annual incidence rate approaches 190 cases/100.000 per year.2 Solitary parathyroid adenoma is the main cause of pHPT in approximately 80% of cases and surgical resection of the pathological gland is curative. The remaining cases are usually secondary to glandular hyperplasia and less commonly, multiple adenomas with parathyroid carcinoma which is the rarest cause.3

As parathyroidectomy improve pHPT the overall reported cure rates may reach 95- 98% 4, 5 so it is mandatory to detect the diseased gland either pre or intra operative. In the 90Th of the last century many studies discussed the utility of either neck ultrasound (US) or sestamibi scan (SS), however recently many studies supported the efficacy of combining

both US and sestamibi scan.2,3, 6

As most patients with primary hyperparathyroidism have a solitary adenoma, many can be treated with unilateral minimally invasive surgical techniques following accurate preoperative localization.3, 7

Ultrasound alone permits localizing the adenoma site in relation to the thyroid gland, detects multiplicity specially if there isn't any nodularity of the thyroid gland and also detects small adenomas. On the other hand, sestamibi has its role in localization specially in ectopic parathyroid (15-20%) and in presence of nodular goiter.3

With the high prevalence of nodular goiter in patients with primary HPT ranging in many series from 25% to 52% sestamibi scan became the most popular preoperative technique of localization.8

Aim of the work:

We aim from this study to evaluate the sensitivity of ultrasound and sestamibi each

separately and in combination aiming to establish a protocol which is reliable as regard the efficacy and the cost effectiveness for detection and localization of hyperfunctioning parathyroid gland(s) to establish the minimally invasive technique of parathyroidectomy as a routine procedure for parathyroidectomy.

Patient and method:

Seventeen patients with primary hyperparathyroidism were operated on over 36 months in Ain Shams University hospitals (March 2009-February 2011). The elevated parathyroid hormone was the main indicator of surgery rather than the ultrasound nor the

sestamibi scan, however none of our patients had renal impairment nor recurrent lesions, and all patients had been informed about the nature of the study and consented. All patients underwent both sestamibi scan and US prior to surgery and the results were compared with operative and histological findings.

Results:

Intra-operative localization and postoperative histopathology showed that out of our 17 pHPT patients there were 14 patients with single adenoma, 2 patients with hyperplasia and a single case with multiple adenomas).

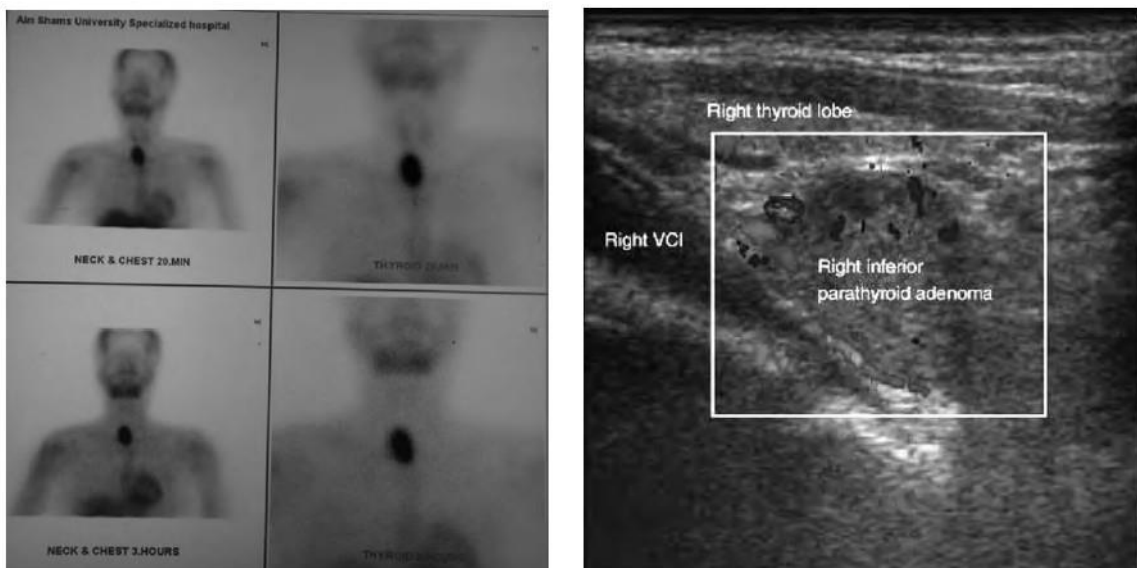


Figure (1): Localization of a right inferior parathyroid adenoma by US & SS.

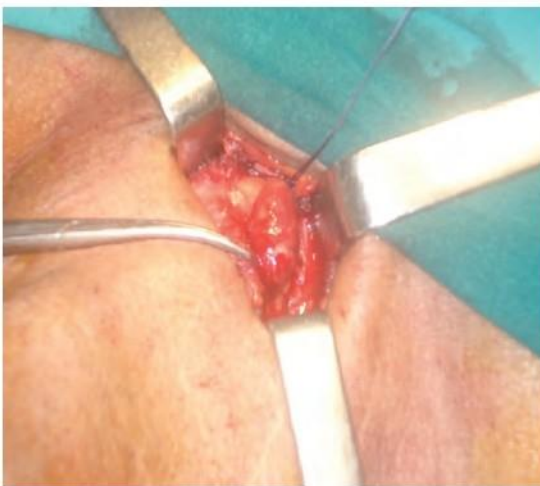

Figure (2): Minimally invasive surgical exposure.

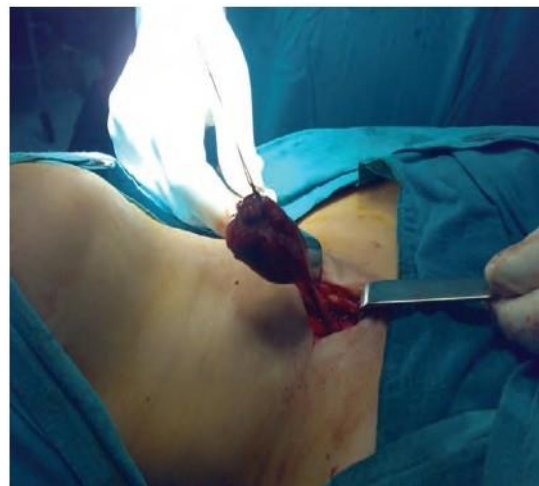


Figure (3): Surgical delivery of the adenoma.

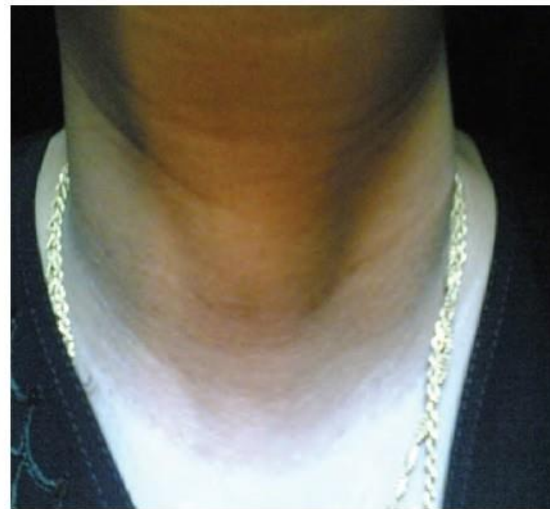
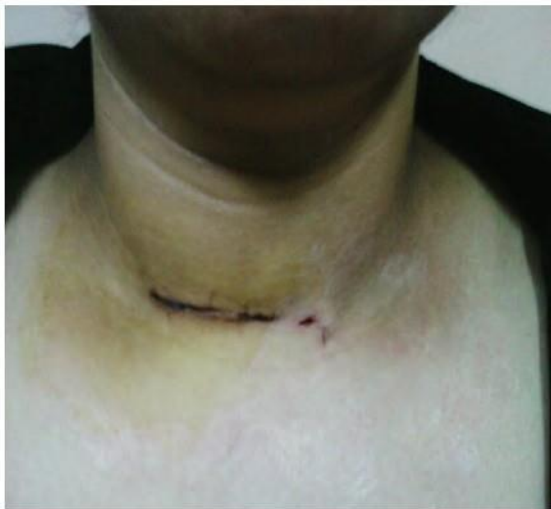

Figure (4): Postoperative wound after 1 week Figure (5): Postoperative wound after 1 year.

Table (1): Results obtained using SS IIIUI US (TP: true positive, FN: false negative).

	TP	FN	Adenoma	Multiple adenomas	Hyperplasia
Ultrasound	10 (59%)	7	9	1	0
Sestamibi scan.	14 (82%)	3	12	1	1
Combined US and sestamibi scan	16 (94%)	1	14	1	1
Operative and histopathology	17		14	1	2

Out of the 10 cases of p:FWT detected by US only 2 cases couldn't be detected by sestamibi scan.

Discussion:

The best localization technique for parathyroid is a capable surgeon, 9,10 though if s one of the most famous statements in surgery many clinical trials were conducted to evaluate and compare the different modalities of localizing hyperfunctioning parathyroid gland(s) to come up with the best protocol that is not only accuratet but also relatively easy and cost effective.

The issue of localizing the diseased parathyroid gland(s) still under debates as some authors reported higher sensitivity of localization if combining both Sestamibi scan and neck ultrasound (88.4% for sestamibi, 82.1% for US and 96.5% if combining both), however many authors found no benefit of this combination 3,6 and others found preoperative localization is of no benefit as in their expert hands bilateral neck exploration results in success rates exceeding 95% with minimal morbidity.11,12

In our study which was performed on only 17 cases we found that the sensitivity of US alone to be only 59% which is low comparing to recent western studies (76-91%), 2 though it isn't far from others 64% 3 and we think this poor value could be operator dependent but this didn't lead us to ignore the role of US as there are 2 patients not detected by sestamibi and detected by US. However we believe that the sensitivity of US may improve using color and power Doppler sonography.

As reported in many studies the sestamibi sensitivity varies from 80% to 92% 8, 12 and in our study it was 82% , this is within the accepted range reported recently in many studies.

We think that the 3 lesions missed on scintigraphy did not show significant tracer uptake to allow detection and/or differentiation from physiological thyroid uptake as the degree of sestamibi uptake in parathyroid adenomas has been reported to correlate with the size of gland and the cytological composition because it's a non-specific tracer that is taken up by mitochondria, and therefore, any mitochondria-rich cells may show uptake (greater uptake is

seen in adenomas with a predominance of oxyphil cells compared to chief cells).

Barczynski et al, 2006 12 claimed their opinion of combination upon the high prevalence of thyroid disease among their cases and they noticed that the sensitivity of combining both techniques was 90.7% in

patients with goiter while when using US or sestamibi in patients with goiter the sensitivity were (53.5%, 60.6% respectively). While Lumachi & co-workers 2003 8 noticed that the sensitivity of combining both techniques is significantly higher than using each regardless the presence of goiter Table(2).

Table (2):Lumachi et al, results as regard the sensitivity of US and sestamibi scan in detecting parathyroid adenoma among patients. B

	No goiter	With goiter
Ultrasound	79%	70.8%
Sestamibi scan	83%	87%
US & sestamibi scan	93.1%	92%

In our study we noticed a significant improvement in sensitivity when we combined both techniques (94%) and amazingly it isn't far from Western studies results but we still think it might not be a true result as we had only 17 patients.

Grosso & co-workers 2007 6 reported that the combination of SS and US does not enhance sensitivity nor specificity compared with either technique used alone and therefore is not cost-effective; however, the 2 methods can be complementary. Though we found there is a significant difference as regard sensitivity between each of the techniques and if combined but we agree with the authors 6 in using both techniques in a complementary manner and we suggest that US should be used first and that sestamibi scan should be reserved for negative US findings, because, unlike US, it can visualize adenomas inferior to the thyroid in sonographically "silent" regions, moreover, SS sensitivity did significantly correlate with the size of the PT adenoma, but not with the site of the abnormal PT glands.

Conclusion:

At the end, we believe that the complementary noninvasive diagnostic protocol will support the minimally invasive parathyroidectomy and then it could be the classic technique of parathyroidectomy.

References:

- 1- Conroy S, Moulias S, Wassif WS: Primary hyperparathyroidism in the older person. *Age and Ageing* 2003; 32(6): 571-578.
- 2- Lumachi F, Zucchetta P, Mazola MC, et al: Advantages of combined technetium-99m-sestamibi scintigraphy and high resolution ultrasonography in parathyroid localization: Comparative study in 91 patients with primary hyperparathyroidism. *European J Endocrinology* 2000; 143: 755-760.
- 3- Patel CN, Salahudeen HM, Lansdown M, Scarsbrook AF: Clinical utility of ultrasound and 99TC sestamibi SPECT/CT for preoperative localization of parathyroid adenoma in patients with primary hyperparathyroidism. *Clinical Radiology J2010*; 65: 278-287.
- 4- Sosa JA, Powe NR, Levine MA, et al: Threshold for surgery and surgical outcomes for patients with primary hyperparathyroidism: A national survey of endocrine surgeons. *J Clinical Endocrinology and Metabolism* 1998; 83: 2658-2665.
- 5- Delbridge LW, Younes NA, Guinea AI, et al: Surgery for primary hyperparathyroidism 1962± 1996. Indications and outcomes. *Medical J of Australia* 1998; 168: 153-156.

- 6- Grosso I, Sargiotto A, D'Amelio P, et al: Preoperative localization of parathyroid adenoma with sonography and 99TC sestamibi scintigraphy in primary hyperparathyroidism. *Clinical Ultrasound J*2007; 35: 186-190.
- 7- Udelsman R: Six hundred and fifty-six consecutive explorations for primary hyperparathyroidism. *Ann Surg* 2002; 235: 655-670.
- 8- Lumachi F, Mazola MC, Zucchetta P, et al: Hyperfunctioning parathyroid tumors in patients with thyroid nodules, sensitivity and positive predictive value of high resolution ultrasonography and 99TC-sestamibi scintigraphy. *Endocrine- Related Cancer J*2003; 10:419-423.
- 9- Bergert H, Zimmermann T, Ockert D, Alldinger I, Kersting S, Saeger HD: Intraoperative chemiluminometric assay for simplified localization of parathyroid adenomas during surgery for primary hyperparathyroidism. *Talanta* 2003; 60: 617-621.
- 10-Hajioff D, Iyngkaran T, Panagamuwa C, Hill D, Stearns MP: Preoperative localization of parathyroid adenomas: ultrasonography, sestamibi scintigraphy, or both? *Clinical Otolaryngol Allied Sci* 2004; 29: 549-552.
- 11-Low RA, Katz AD: Parathyroidectomy via bilateral cervical exploration: A retrospective review of 866 cases. *Head and Neck* 1998; 20:583-587.
- 12-Barczynski M, Golkowski F, Kontw'ek A, et al: Technetium-99m-sestamibi subtraction vs. ultrasonography combined with a rapid parathyroid aspirates in preoperative localization of parathyroid adenomas and in directing surgical approach. *Clinical Endocrinology J* 2006; 65: 106-113.